

---

# Ridge Widening for the Thin Maxilla: A Clinical Report

James M. Duncan, DDS\*/R. Mikel Westwood, DDS\*\*

---

The thin maxilla may present an anatomic limitation to the placement of endosseous implants. Separating the cortical plates and widening the alveolar ridge with simultaneous placement of implants is one surgical method for management of this problem. Guided tissue regeneration techniques may be used in conjunction with this ridge widening procedure.

(INT J ORAL MAXILLOFAC IMPLANTS 1997;12:224-227)

**Key words:** guided tissue regeneration, implant, ridge widening, thin maxilla

---

The complete and partially edentulous maxilla may exhibit inadequate bone for implant placement. Bone grafting,<sup>1-3</sup> use of membranes for guided tissue regeneration,<sup>4-11</sup> and ridge widening procedures<sup>6,12,13</sup> have been utilized in the treatment of this problem. A technique is described for placing implants with sufficient bone height but insufficient width. This report describes a technique for separating and widening the maxillary cortical plates to facilitate the placement of endosseous implants. The procedure differs from other published techniques in that the labial cortical plate is completely exposed and separated with a No. 700 fissure bur. A deep "trench" is created, allowing widening of very narrow alveolar bone. The procedure can be considered for the following reasons:

1. To widen thin alveolar bone when a standard osteotomy cannot be prepared
2. To improve the angle of the implant in the alveolar bone

3. To allow the use of a larger-diameter implant
4. To separate the cortical plates for grafting or guided tissue regeneration
5. To elevate the sinus floor in selected patients

## Materials and Methods

The edentulous area of the maxilla from premolar to premolar usually exhibits the most severe labial and buccal bone resorption. However, a thin alveolus can occur in any area. The anterior maxilla, particularly the esthetic zone, must be evaluated for alveolar bone height, width, and angulation. From the soft tissue stand point, evaluation of the patient lip line is important. If angulation of the implant will compromise the restoration and esthetics, ridge widening alone is not the treatment of choice. In partially edentulous patients, alveolar bone height in relation to adjacent teeth is important when considering the length of the clinical crown of the restoration. Length of the clinical crown is not as much of a concern with a low lip line as in a patient with a high lip line.

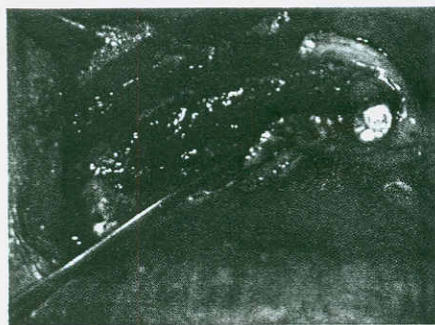
Patient evaluation includes a medical and dental history, clinical examination, and radiographs. Standard radiographs consist of panoramic and cephalometric views, and computerized tomographic scans or tomograms when indicated. Ridge mapping under local anesthetic with either a sharp periodontal probe or a ridge mapping instrument can be helpful.<sup>14</sup> The ridge mapping instrument resembles a towel clip calibrated in millimeters at the handle, and it is used to measure bone width by penetrating the labial and palatal gingivae.

---

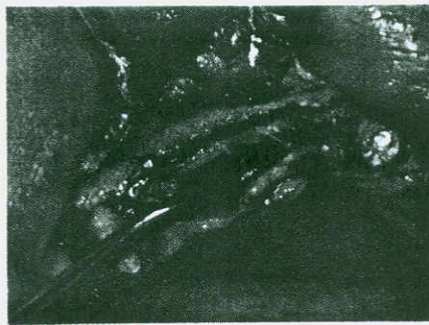
\*Private Practice, San Antonio, Texas; Clinical Associate Professor, Department of Oral and Maxillofacial Surgery, University of Texas Health Science Center, San Antonio, Texas.

\*\*Private Practice, San Antonio, Texas; Clinical Professor, Department of Oral and Maxillofacial Surgery, University of Texas Health Science Center, San Antonio, Texas.

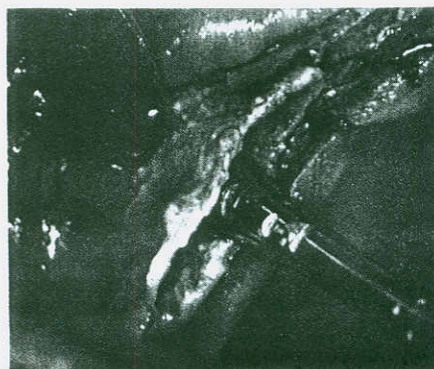
**Reprint requests:** Dr James M. Duncan, 8647 Wurzbach Road, Suite K, San Antonio, Texas 78240.



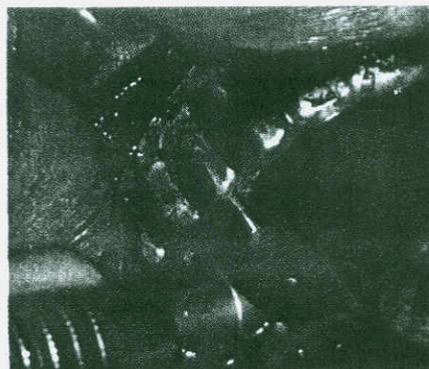
**Fig 1a** Narrow maxillary anterior alveolar ridge; the most narrow area is superior to the crest.



**Fig 1b** Alveolar bone with a channel or groove prepared with 700 fissure bur. The bone superior to the crest is the most narrow.



**Fig 1c** Widening process initiated with flat, tapered osteotome.



**Fig 2** Once the ridge has been widened to 2 mm, a 1.5-mm twist drill is used to establish the position of the implant with the aid of a surgical guide.

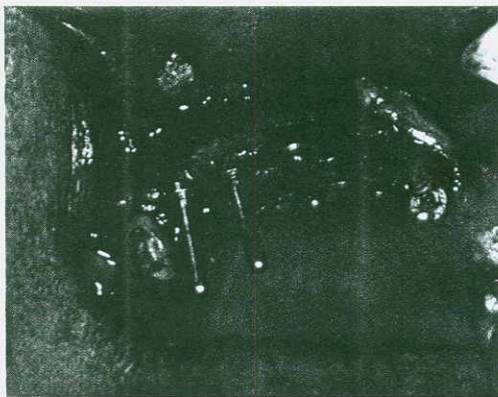
The widening instruments consist of a No. 700 fissure bur, 1.5-mm and 2.0-mm twist drills, a tapered spade chisel, and a series of round osteotomes 2.0, 2.6, 3.2, 3.7, and 4.0 mm in diameter (H & H Instrument, Ontario, CA).

**Procedure.** Alveolar ridge exposure in the maxilla is achieved through a crestal ridge incision slightly toward the palate. The mucoperiosteum is elevated on the labial side to expose the complete height of the alveolar bone (Fig 1a). Tissue relaxation for a tension-free closure is critical and is achieved by incising the periosteum in the buccal fold area. The bone can be visually examined and measured, and the final decision can be made to place implants, use an interpositional or onlay bone graft, or perform a ridge widening procedure.

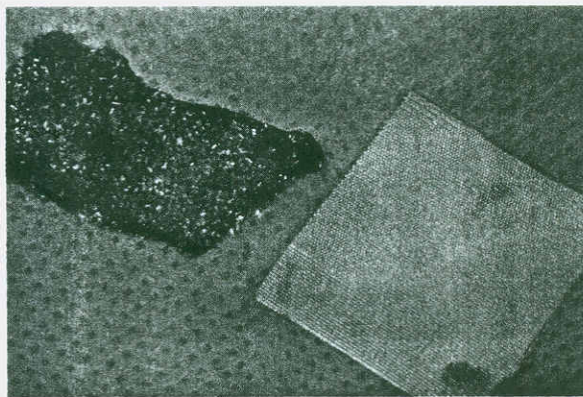
If a widening procedure is to be done, a No. 700 fissure bur in a straight handpiece is used to create a channel along the crest of the alveolar bone (Fig 1b). This channel should be as long and deep as possible to completely separate the cortical plates, reduce the

incidence of cortical plate fracture, or control the location of the fracture. Cortical plate fractures are not a major concern if the plate maintains its superior attachment and the implant or graft is stable. Following cortical plate separation with the No. 700 fissure bur, the spade chisel is used to begin the widening process (Fig 1c). The plates are widened to approximately 2 mm, a surgical template is placed, and a 1.5- or 2.0-mm twist drill is used to establish the position and depth of the implant (Fig 2).

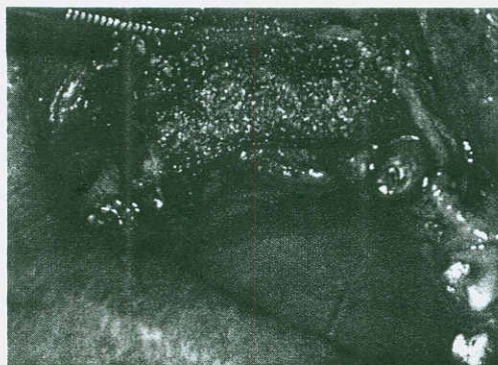
The round osteotomes are next used, starting with either the 2.0- or 2.6-mm diameter. Care should be taken to follow the path established in the bone with the twist drill. The surgical guide can be reinserted and used with the round osteotomes if necessary. The osteotome is tapped with a mallet to the maximum depth possible. If there is adequate bone, the 3.2- or 4.0-mm-diameter osteotome may be used. Good separation of the plates should be achieved, and the implant site will appear as a trench (Fig 3). The implant may be firmly seated, even in very thin bone,



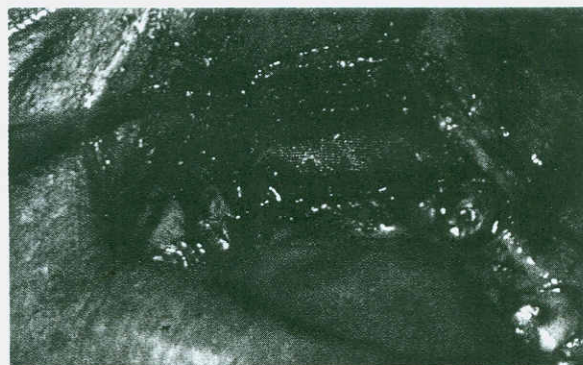
**Fig 3** The ridge has been widened to 3.2 mm. Paralleling pins are in position, indicating the implant positions.



**Fig 4a** Collatape is "battered" on both sides with moistened DFDB and Osteogen. Also seen is a polyglactin 910 mesh membrane.



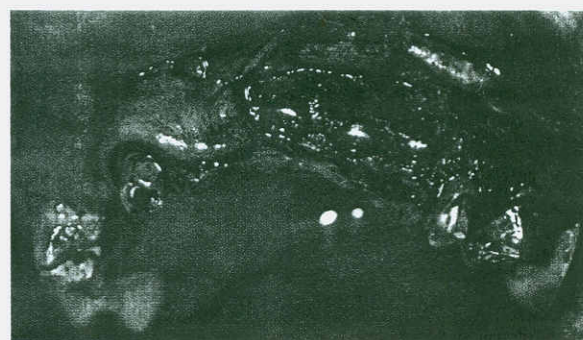
**Fig 4b** The battered collatape is placed in position and covers the implants and alveolar bone. No attempt is made to fill the space between the cortical plates with graft material.



**Fig 4c** Polyglactin 910 mesh membrane in position covering the battered collatape.

because the cortical plates spring back somewhat, and the 3.2-mm osteotome is 0.1 mm smaller than the 3.3-mm cylinder implant, and 0.55 mm smaller than the 3.75-mm threaded implant. The diameter of the implant to be placed is determined by the amount of the cortical plate separation that can be achieved and still have a stable implant.

To help stabilize the implant, the cortical bone at the floor of the sinus is usually penetrated with a twist drill or round osteotome. The floor of the sinus may be elevated slightly (2 to 4 mm) with the osteotome. However, the floor of the nose is usually not penetrated because of a greater chance for infection. Stability can be determined by observing how secure the round osteotome becomes once it is tapped into position. After the implant has been placed, a guided tissue regeneration procedure may be necessary. The same procedure is followed in placing a single implant between two natural teeth.



**Fig 5** Stage 2 surgery. Note the excellent bone growth that occurred between the cortical plates, as well as additional labial bone apposition.

The membrane selected for guided tissue regeneration depends on the thickness of the cortical plates after widening. In early cases where no membrane was used, the widened area was grafted with a combination of porous hydroxyapatite and demineralized freeze-dried bone (DFDB) or autogenous bone grindings, and the mucoperiosteum was sutured. In situations where a very thin cortical plate exists after implant placement, or significant fractures have occurred, moistened collatope is "battered" with powdered or gel-form DFDB, or autogenous bone grindings, or both, plus approximately 10% calcium phosphate (Osteo Gen, Impladent, Holliswood, NY) (Fig 4a), and it is placed in the desired location (Fig 4b). This is covered with either an expanded polytetrafluoroethylene (e-PTFE) membrane (Gore-Tex, WL Gore, Flagstaff, AZ) or polyglactin 910 (Vicryl, Ace Surgical Supply, Brockton, MA) mesh (Fig 4c). No attempt is made to fill the space between the separated cortical plates with graft material. It is of primary importance that good tissue relaxation be achieved and closure be accomplished without tension. The same care must be taken with tissue management in ridge widening procedures as in situations where autogenous bone grafting is done. Abutment surgery is performed after 6 months of healing. Figure 5 shows the results obtained using the polyglactin 910 mesh membrane.

### Discussion

Both screw and cylinder implants have been used successfully during the past 6 years in maxillary alveolar bone having less than 4 mm in width. Because the cylinder implant is tapped into position, it is easier to use and has a slightly higher success rate; however, 90% of the implants placed during the past 6 years are still in function. A variety of prostheses have been used, including overdentures, and single-tooth, implant-to-natural tooth, and implant-to-implant fixed removable prostheses.

Sound guided tissue regeneration principles and techniques are vital to the overall success of ridge widening. A variety of membranes have been used. However, the purpose of this report was not to compare different guided tissue regeneration techniques or membranes; it is the opinion of the authors that any one of several techniques will be successful if used in a proper manner.

### Summary

Ridge widening with immediate implant placement, along with guided tissue regeneration procedures, has been shown to be very predictable and successful

in treating the thin maxilla. As with any implant treatment, presurgical planning is crucial to the outcome. Function and esthetics are equally important. Patient selection includes considering the alveolar bone height, width, and angle, along with the lip line position of the patient and the type of prosthesis to be used. No longer does implant position determine the restoration; to a much greater degree, the restoration determines the implant position.

### References

1. Adell R, Lekholm U, Gröndahl K, Brånemark P-I, Lindström J, Jacobsson M. Reconstruction of severely resorbed edentulous maxillae using osseointegrated fixtures in immediate autogenous bone grafts. *Int J Oral Maxillofac Implants* 1990;5:233-246.
2. Collins T. Onlay bone grafting in combination with Brånemark implants. *Oral Maxillofac Surg Clin North Am* 1991;3:893-902.
3. Nyström E, Kahnberg K-E, Gunne J. Bone grafts and Brånemark implants in the treatment of the severely resorbed maxilla: A 2-year longitudinal study. *Int J Oral Maxillofac Implants* 1993;8:45-53.
4. Nyman S, Lang N, Buser D, Brägger U. Bone regeneration adjacent to titanium dental implants using guided tissue regeneration: A report of two cases. *Int J Oral Maxillofac Implants* 1990;5:9-14.
5. Schultz AJ, Gaper AH. Guided tissue regeneration using an absorbable membrane (polyglactin 910) and osseous grafting. *Int J Periodont Rest Dent* 1990;10:9-17.
6. Buser D, Brägger U, Lang S. Regeneration and enlargement of jaw bone using guided tissue regeneration. *Clin Oral Implants Res* 1990;1:22-32.
7. Nyman S. Bone regeneration using the principle of guided tissue regeneration. *J Clin Periodontol* 1991;18:494-495.
8. Nevins M, Mellonig JT. Enhancement of the damaged edentulous ridge to receive dental implants: A combination of allograft and Gore-Tex Membrane. *Int J Periodont Rest Dent* 1992;12:97-111.
9. Godefroy JN, Laroche N, Fourcart J, Boivin G. Ridge reconstruction after implant failure using a resorbable membrane: Report of a case and histologic study. *Int J Oral Maxillofac Implants* 1994;9:431-435.
10. Dahlin C, Lekholm U, Becker W, Becker B, Higuchi K, Callens A, van Steenberghe D. Treatment of fenestration and dehiscence bone defects around oral implants using the guided tissue regeneration technique: A prospective multicenter study. *Int J Oral Maxillofac Implants* 1995;10:312-318.
11. Augthun M, Yildirim M, Spiekermann H, Biesterfeld S. Healing of bone defects in combination with immediate implants using the membrane technique. *Int J Oral Maxillofac Implants* 1995;10:421-425.
12. Massimo S, Baldoni M, Zaffe D. Jawbone enlargement using immediate implant placement associated with a split-crest technique and guided tissue regeneration. *Int J Periodont Rest Dent* 1992;12:463-473.
13. Summers R. The ridge expansion osteotomy (REO). *Compend Contin Educ Dent* 1994;15:422-436.
14. Wilson DJ. Ridge mapping for determination of alveolar ridge width. *Int J Oral Maxillofac Implants* 1989;4:42-43.