

# The Sinus Lift Procedure: An Alternative to the Maxillary Subperiosteal Implant

David M. Vassos, D.D.S.

Peter K. Petrik, M.D., F.R.C.P.C.

*Technical advances now allow implants to be placed when pneumatization of the sinus has left insufficient bone to engage an endosseous implant. Augmenting material, such as a mixture of resorbable hydroxylapatite and demineralized freeze-dried bone, is grafted into the sinus cavity. This creates a new alveolar ridge to support endosseous implants.*



ental implants are becoming a standard treatment for patients when there is adequate bone and

no contraindications, but the treatment of patients with pneumatization of the sinus and insufficient remaining bone to engage endosseous implants remains a challenge. During the past 15 years, stabilization of the prosthesis has been achieved by reliance on the full maxillary and unilateral pterygoid extension subperiosteal implant, but the success rate has been considerably lower than when used on the mandible, thus inspiring the search for an alternative.<sup>1</sup>

New developments in the 1970s included the tuber blade,<sup>2</sup> the aluminum oxide wide-blade sinus implant, and the sinus-bar implant, which elevated the sinus membrane while engaging mesial and distal bone.<sup>3</sup> While some success was achieved with each of these, they did not provide an acceptable level of predictability.

Tatum was among the first clinicians to suggest altering the sinus cavity by raising the sinus floor and placing bone grafts for the purpose of supporting endosseous implants to stabilize a maxillary prosthesis.<sup>1</sup> Since his presentations in the late 1970s, other clinicians have used this procedure, employing a variety

of materials and methods. Contraindications to this approach include uncontrolled diabetes, alcohol or substance abuse, mental instability, carcinoma of the oral tissue, ongoing radiation therapy, and uncontrolled endocrine or cardiovascular disease. This article describes the materials and procedures used in a series of 35 sinus lift operations.

## AUGMENTING MATERIALS

A number of materials have been used to raise the sinus floor in anticipation of placing endosseous implants.<sup>4-11</sup> Initially, autogenous bone harvested from the tuberosity or the iliac crest was the graft material of choice because of its innate biocompatibility. Subsequently, the use of allografts, such as frozen bone, freeze-dried bone, and demineralized freeze-dried bone became more common because their use eliminated donor site surgery. (Demineralizing bone is the process by which the inorganic matrix is removed, releasing bone morphogenetic proteins. This process is thought to speed the osteogenic process.)

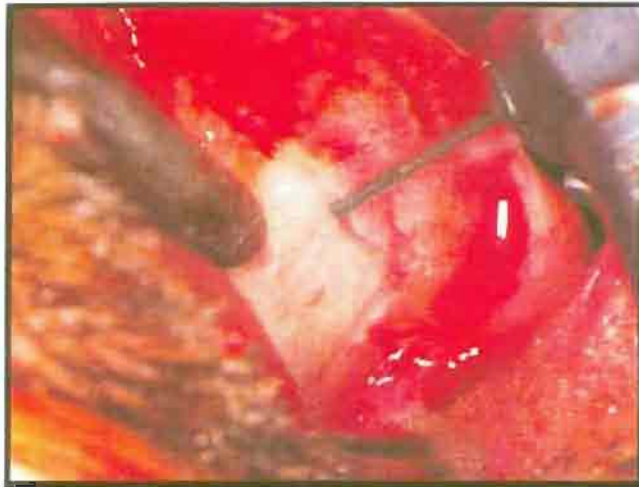
Increasingly, hydroxylapatite (HA) mixed with allograft material is becoming an augmentation material of choice. HA is a generic classification of calcium phosphate materials that resorb at a rate related to porosity, crystal size, and density. Synthetic or naturally derived highly microporous

HA products are thought to determine the rate of degradation, and thus may ultimately be responsible for biodegradability and replacement with bone.<sup>12</sup> The osteoconductive HA acts as a bridge for the new bone, whose formation is induced by the presence of freeze-dried bone.<sup>13</sup> Although some clinicians mix saline solution with the material, we prefer to use autologous blood with a liquid A/B (Keflin) to form a thick, putty-like mass that is easily manipulated.

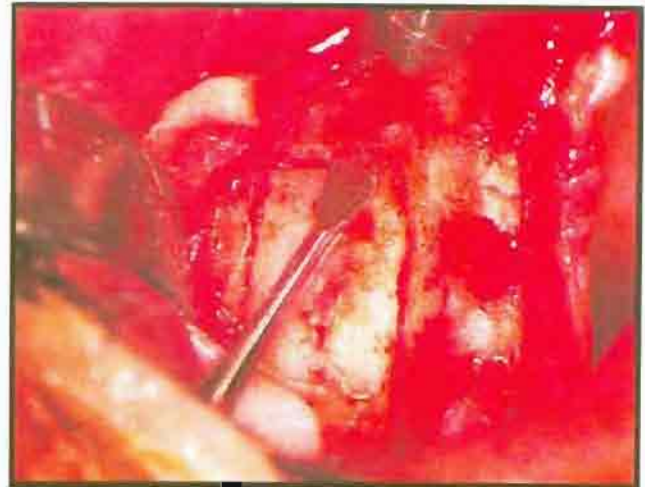
## THE GRAFT PROCEDURE

Prior to beginning the sinus lift procedure, obtain clear radiographs to identify the inferior border of the sinus. This will ensure the proper placement of the antral opening. The steps involved in the graft procedure are as follows:

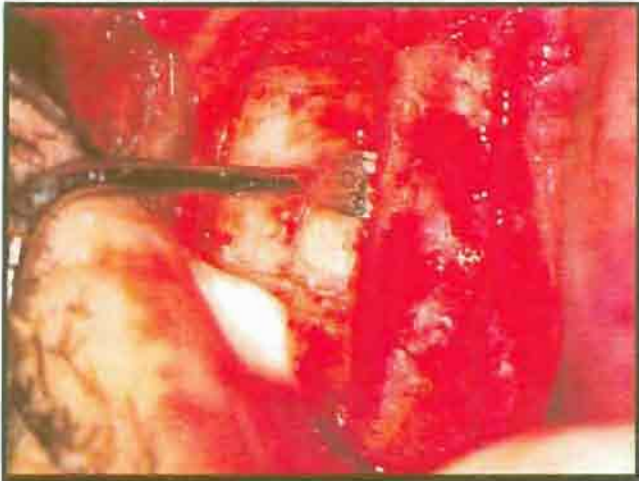1. Make a 2 to 3 mm incision on the palatal side of the crest of the ridge, with a releasing incision at least 15 mm mesial to the antral opening.
2. Reflect a full-thickness mucoperiosteal flap from the crest of the ridge back to the tuberosity and high up on the buccal plate of bone. If a buttress exists between two areas planned for implant support, a small window is made at the exact location of



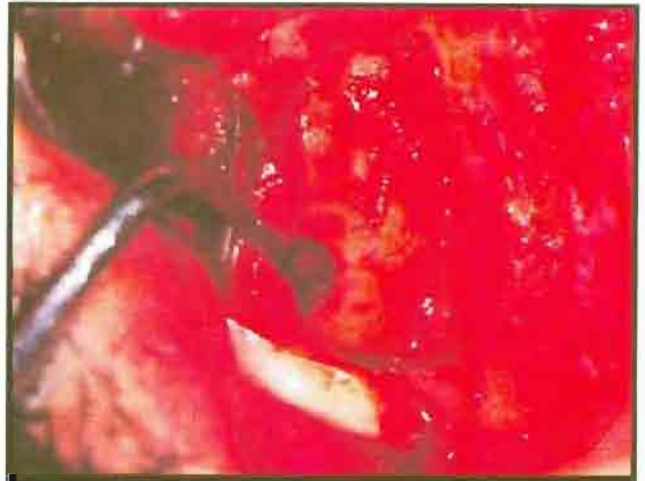**Figure 1.** 701 tapered fissure burr, held at 45-degree angle, used to score buccal plate of bone.



**Figure 2.** Curette, used to press against window to detect movement.

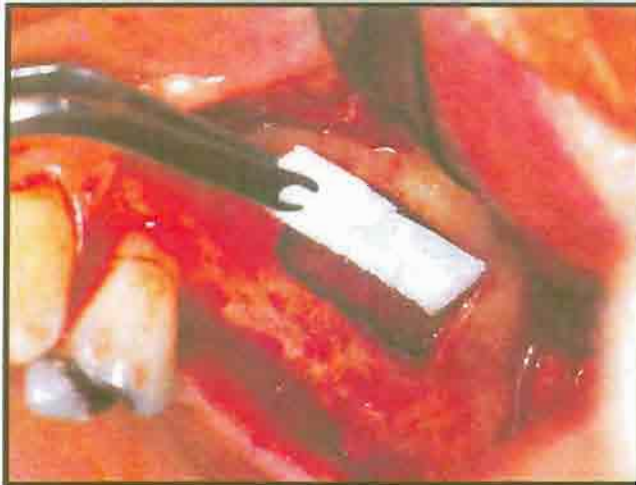

**Figure 3.** Curette, used to peel membrane away from inside wall of sinus cavity.

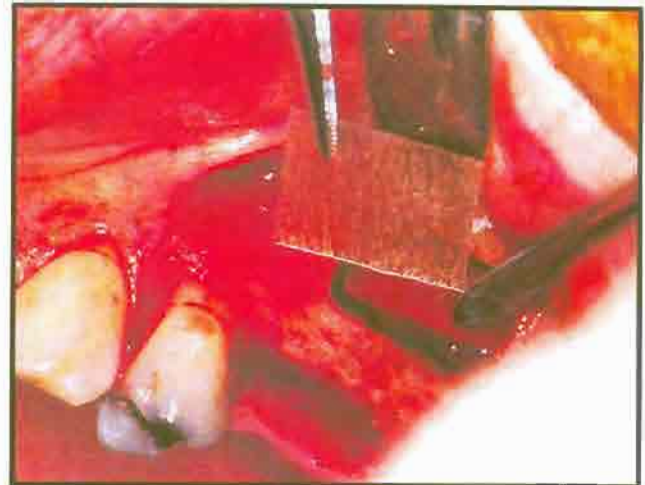


**Figure 4.** Window with membrane reflected back.

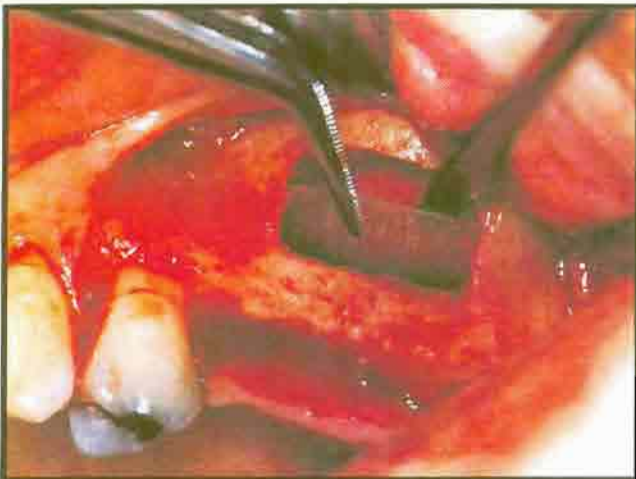- each implant. Two separate windows are created with two separate grafts.
3. Using a tapered fissure bur, held at a 45-degree angle to the surface of the bone, outline a rectangular bony flap (Figure 1).
4. With delicate paintbrush strokes, score the bony plate, taking extreme caution not to touch the underlying Schneiderian membrane. (The delicacy required here is similar to that needed to cut through an eggshell without cutting through the membrane beneath it.)
5. While cutting through the thin plate of bone, intermittently press the convex side of a large surgical curette against the window, while watching for slight movement (Figure 2).
6. Combine scoring in this manner until movement is evident.
7. As the plate begins to weaken, engage a surgical curette under the inferior margin between the bone and the Schneiderian membrane (Figure 3).
8. With a sliding motion, push in the window of bone and, at the same time, peel the underlying membrane from the inside wall of the sinus. Some operators have suggested using a fracture technique for pushing in the window of bone by gently tapping a blunt chisel placed in the outline of the flap. The fracture technique, however, affords less control than the curette procedure, and increases the likelihood of tearing the sinus membrane when the bone fractures. The curette technique allows the membrane to be carefully reflected back in place, thus preserving it intact (Figure 4).
9. When the sinus membrane is intact, a bellows effect may be observed as the patient breathes. If a tear occurs in the membrane, place a small piece of resorbable collagen (collatape) barrier material against the tear, where it should easily adhere. Check again for the bellows effect (Figure 5). If a larger tear occurs in the Schneiderian membrane, (Pacific Coast Tissue Bank, Los Angeles, CA ) LAMINAR BONE (membrane-like sheets of demineralized freeze-dried human laminar cortical bone - 20-100 microns thick, in sizes up to 20 x 20 mm) can be used to easily repair it (Figures 6 to 8).



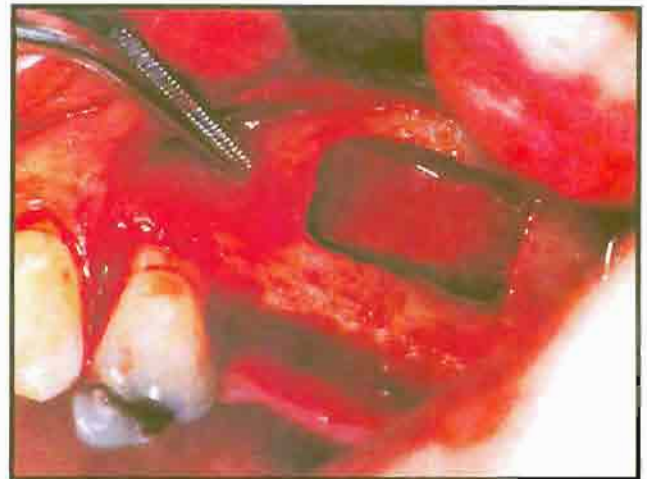
**Figure 5.** 'Collatape' used to repair small tear of Schneiderian membrane.



**Figure 6** Thin sheet of 'Laminar Bone'.



**Figure 7.** New superior wall of sinus erected with 'Laminar Bone'.



**Figure 8.** 'Laminar Bone' in place.

A healthy sinus membrane is extremely thin, yet thick enough to allow for a successful lift operation. Of the 35 sinus lift procedures in this study, only one case was encountered in which a sinus membrane was nonexistent, rendering the procedure impossible to perform. A patient with a history of sinus infections will likely have a very thick membrane that is highly resistant to tearing. No implant or graft should be placed, however, if infection is present.

The sliding curette technique is only used on the mesial, distal, and inferior border of the window, allowing the superior border to act as a hinge. The hinge action may be enhanced by placing a series of closely spaced holes along the superior border and scoring only part way through the bone. If enough bone exists, inferior to the maxillary sinus in which

to stabilize root form implants, implants can be placed at the same time that the sinus lift procedure is performed. Enough bone is needed for the root form implant to engage and prevent any movement during healing. Usually a minimum of 8 mm is necessary (Figures 9 to 11). In cases of insufficient bone inferior to the sinus but adequate bone mesial and distal to it, a submersible blade implant may be the implant of choice because the blade can engage the bone flanking the sinus, which will stabilize it during the healing phase.

#### **THE IMPLANT PROCEDURE**

When existing bone is minimal, as is typical in sinus lift cases, a submersible blade implant may be indicated. When sufficient bone is present, a root form implant is preferred because there is less danger of

cutting the membrane while preparing the osteotomy. When the opening is very large and there is considerable bleeding, it is sometimes difficult to avoid the membrane when preparing the osteotomy for the blade. A root form implant is more precise because a large surgical curette can be placed under the drill as it enters the opening. At the same time, the curette pushes back the plate of bone, assuring that the membrane will not be torn. The procedure for blade implants follows.

1. Have the patient begin antibiotic therapy the morning of the surgery. If a blade is to be placed at the time of the sinus lift procedure, place the osteotomy along the crest of the ridge in the usual fashion.

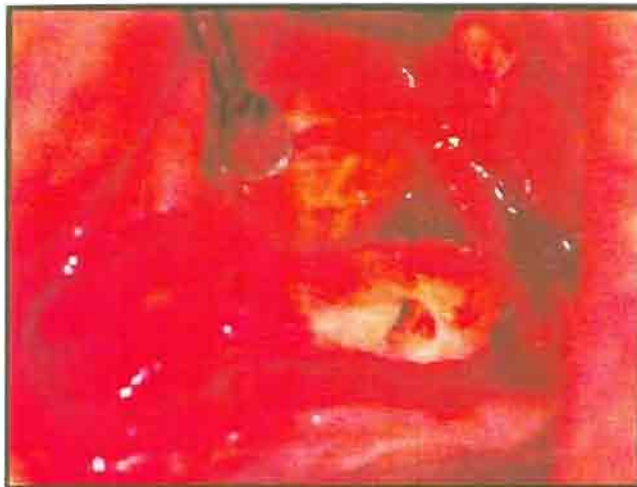

Figure 9. Osteotomy prepared for root forms in conjunction with sinus lift.

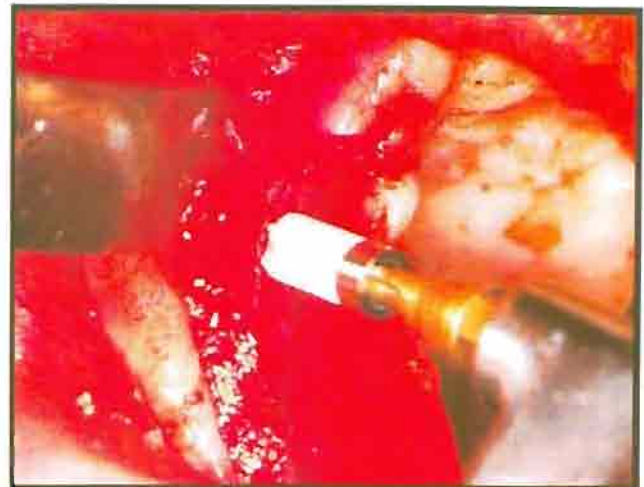


Figure 10. HA-coated implant with OsteoGen® graft material.

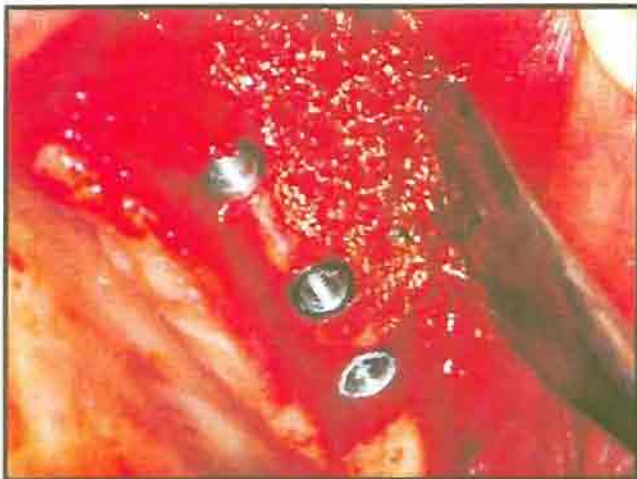

Figure 11. Sinus grafted and root forms in place covered with OsteoGen®.

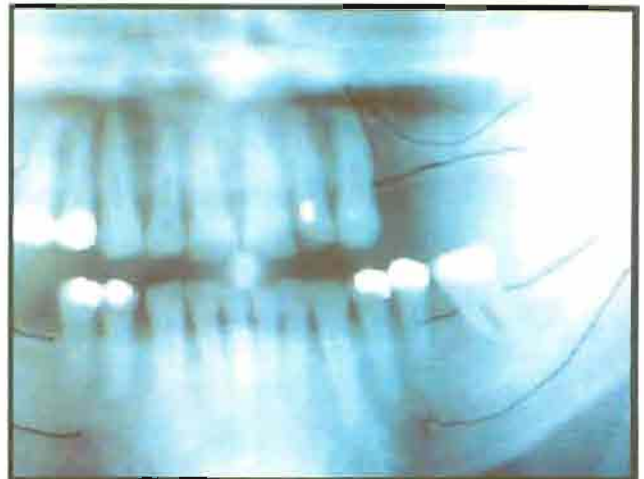


Figure 12. Radiograph showing bone mesial and distal to low sinus floor that is adequate for stabilization of the submersible blade implant.

2. While pressing back the bony plate and sinus membrane, the blade is tried in first to assure proper fit.
3. Remove the blade and fill the sinus cavity with the graft material.
4. Pack the material against the hinged window of bone, which will become the new superior wall of the sinus.
5. Once the sinus is filled with graft material, tap the blade or root form implant into the osteotomy, and press it into the graft (Figures 12 to 16).

Root form implants may be placed in the same manner if there is enough remaining bone to stabilize the remaining implants. If there is insufficient

bone to engage either root forms or blades, perform the sinus lift procedure and allow the site to heal for 6 months before placing the implants. After the graft is in place, cover the sinus window with collatape and suture the tissue back in place.

Instruct the patient to take a decongestant and not to blow his or her nose for at least one week after the surgery. Relieve the buccal flange of the denture so that it does not press against the grafted area and create a dehiscence.

### STUDY RESULTS

To date, we have performed a total of 108 sinus lift procedures. This study consisted of 35 sinus lift procedures on 28 patients. Twelve lifts were grafted with only resorbable HA, 13 with a 50/50 mix of resorbable HA and dem-

ineralized freeze-dried bone, and 3 were grafted with resorbable HA and a non-porous (dense/non-resorbable) HA. In 23 patients, implants were placed in combination with the lift procedure, while 5 patients were allowed to heal for 6 months before implants were placed. Our overall success rate in this study has been 100%. These patients have been followed up for 3-1/2 years, and there have been no clinical changes.

In every case, the implants were clinically solid, with no complications five to nine months later. Clinical observations and bone biopsies, obtained in 4 cases, found that the new bone appeared harder when only resorbable HA was used rather than the HA/freeze-dried bone combination, but no clinical differences in the cases were observed. All surgical procedures were uneventful, with minimal pain and swelling. No sinus complications have

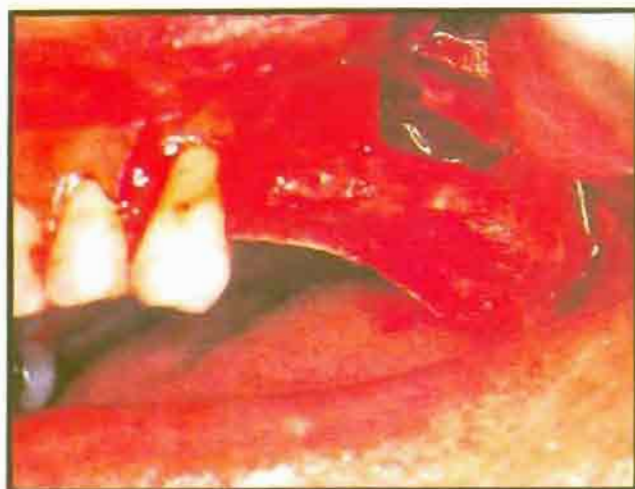

Figure 13. Sinus lift completed before blade placement

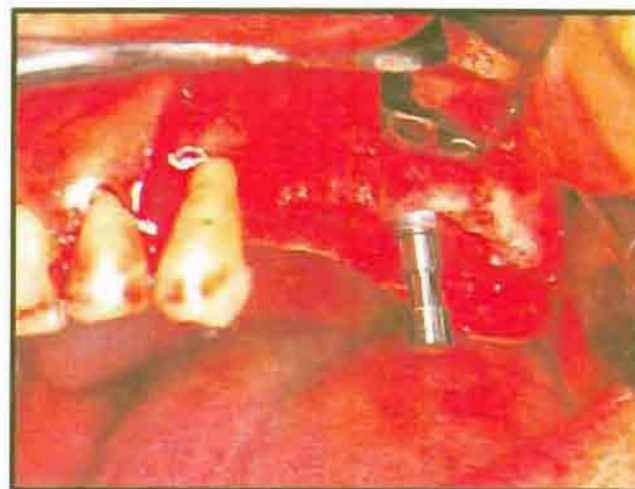

Figure 14. The carrying pin, used to deliver the submergible blade implant in and out of the osteotomy.

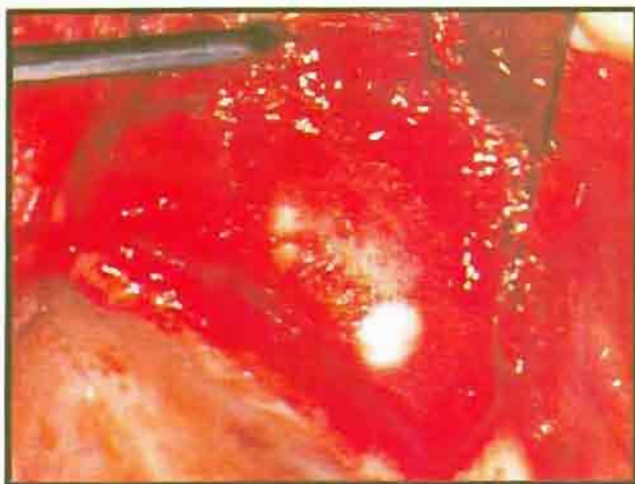


Figure 15. Submergible blade implant in place at time of sinus lift. Graft covered with 'Collatape' barriers.

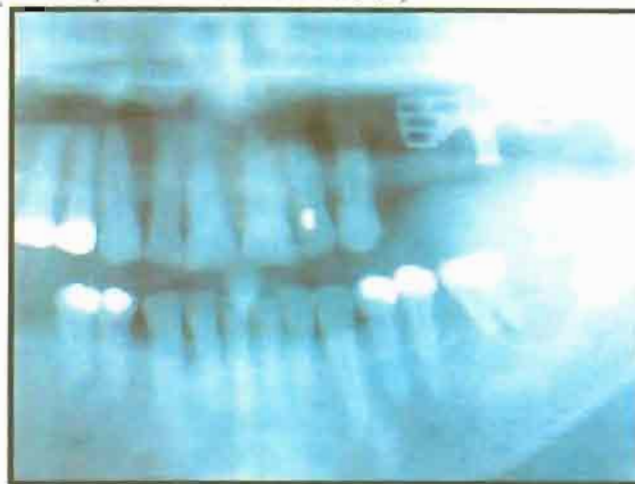


Figure 16. The submergible blade implant, placed with the sinus lift procedure. The site was allowed to heal for 6 months prior to loading.

been encountered to date. In one case, the buccal flange of the denture cut through the tissue and exposed the graft, which healed uneventfully.

Samples of bone were obtained at the time of implant placement (5 to 9 months after placement of the graft). The samples were obtained by passing a trephine drill through the wall opening directly into the graft site in areas not intended for implant placement.

All the biopsies obtained in this manner were lightly decalcified in a commercial solution after an overnight fixation in buffered 10% formalin. Routine histologic sections were prepared from formalin-fixed paraffin-embedded tissue and were stained with hematoxylin and eosin. Morphologic analysis of the bone-induction properties of the various components used in the clinical trial was carried out in a semi-quantitative manner. All case

biopsies showed marked active new bone formation in relation to both HA crystals and freeze-dried bone (Figures 17 to 20).

This morphologic approach did not allow for the evaluation of the contribution of autologous blood to the bone induction. Typically, HA crystals appeared to be engulfed within the newly-formed woven bone. With respect to the freeze-dried bone, remnants can be identified embedded within and fused with new woven bone.

### DISCUSSION

Interestingly, there was no evidence of osteoclastic resorption of the particles of freeze-dried bone in any of the biopsies. We interpret these findings to indicate strong, active, inductive properties of both the HA crystals and the freeze-dried bone. Since these two

components were used simultaneously and in combination in all cases, we are unable to comment on the possible synergistic or potentiating action of the inducers.

The amount and density of the newly formed bone, evaluated microscopically on biopsies in the present series, does not appear to correlate simply with the time elapsed from the procedure. In fact, the heaviest bone formation was found in a patient who underwent biopsy seven months following the procedure.

One factor that interferes with the quantitative correlation is the actual sampling of the induced bone. In the case of a patient who underwent biopsy five months after the procedure, areas were found with much more definite bone formation. This was similar to another case in which the biopsy was carried out at nine months

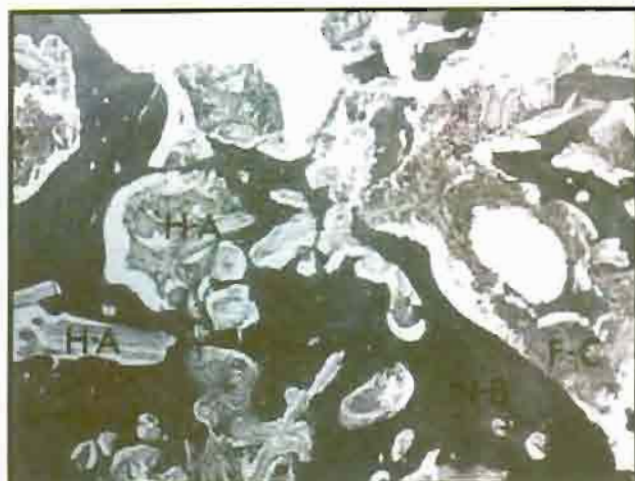

Figure 17. Bone formation at nine months, biopsy showing the fingerprint of OsteoGen® crystals.

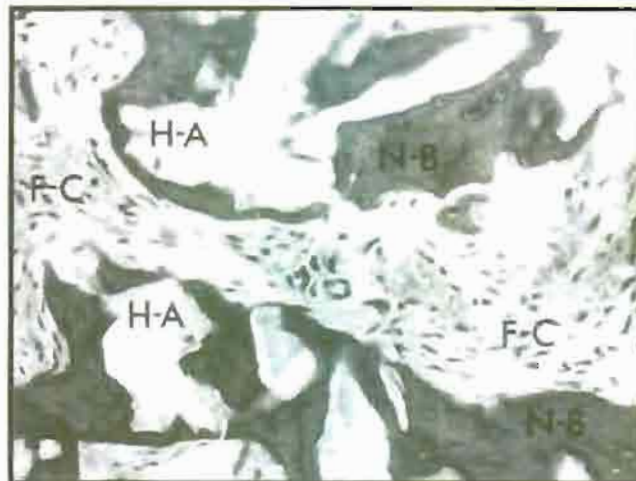


Figure 18. Bone formation at nine months, biopsy

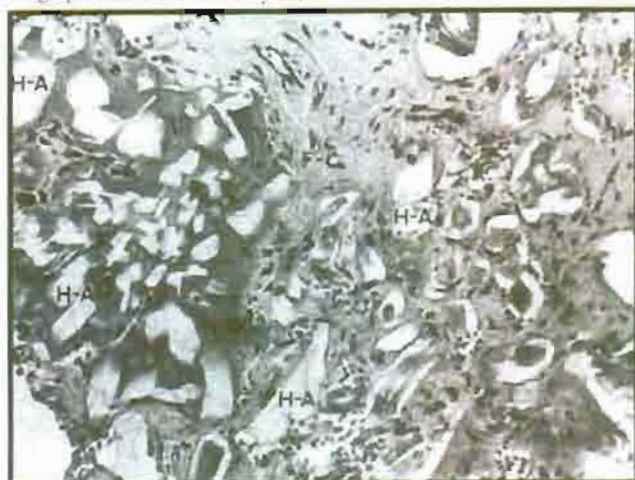


Figure 19. Earliest phase of bone induction.

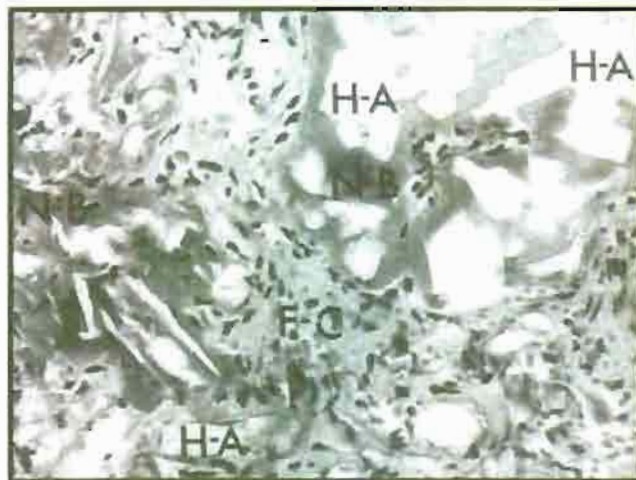


Figure 20. Earliest phase of bone induction showing OsteoGen® synthetic clusters.

(Figures 17 and 18). The areas illustrated were selected to demonstrate the earliest phase of bone induction (Figures 19 and 20).

In addition to the sampling-related issue, there are likely to be other as-yet-undetermined factors influencing the rate of formation and the amount of induced bone.

### CONCLUSION

The results of the 28 cases presented here demonstrate the usefulness of the sinus lift procedure in the treatment of those dental implant candidates who have experienced pneumatization of the sinus resulting in a significant deficiency of alveolar bone. The procedure as described is a relatively simple, predictable technique that enables clinicians to extend endosseous implant treatment to patients who would otherwise be

rejected for insufficient bone. As such, the sinus lift merits inclusion in the armamentarium of the implant specialist.

*Dr. David M. Vassos is a Fellow of the American Academy of Implant Dentistry, Fellow and Diplomat of International Congress of Oral Implantologists, and Diplomat, American Board of Oral Implantologists. He also maintains private practice in Edmonton, Alberta, Canada, specializing in dental implantology.*

*Dr. Peter K. Petrik is a physician at the General Hospital (Grey Nuns) of Edmonton, Alberta, Canada, Department of Laboratory Medicine. He also maintains private practice in Edmonton.*

### REFERENCES

1. Chanavaz M. Maxillary sinus. *J Oral Implant* 1999;16(1):199.
2. Linkow LJ. Tubor blades. *Oral Implant* 1980;9(2):190.
3. Vassos DM. Sinus bar implant. *Oral Implant* 1981;9(4):571.
4. Kahn LB, Mulliken JB, Glowacki J. Treatment of jaw defects with demineralized bone implants. *J Oral Maxillofac Surg* 1982;40:623-626.
5. Dragoos MR, Sullivan HC. A clinical and histologic evaluation of autogenous iliac bone grafts in humans, Part I. Wound healing after 2 to 8 months. *J Periodont* 1970;41:566.
6. Burchard H. The biology of bone graft repair. *Clin Orthop* 1983;174:28-32.
7. Masters JB. Bone and bone substitutes. *CDA* 1988; January.
8. Urist MR, Strates BS. Bone morphogenic protein. *J Dent Res* 1972;50:1392.
9. Schaffhorn RH, Hiatt WH, Boyce W. Ilac transplants in periodontal therapy. *J Periodont* 1972;43:3.
10. Chanavaz M. Lectures on maxillary reconstruction. Alabama Implant Congress, Birmingham, Alabama, 1985.
11. Mellong JT, et al. Clinical evaluation of freeze dried bone allografts in periodontal osseous defects. *J Periodont* 1976;47:125.
12. DeGroot K. Bioceramics consisting of calcium phosphate salts. *Biomaterials* 1980;1:47.
13. Mellong JT, Bowers GM, Cotton WR. Comparison of bone grafting materials, Part II. New bone formation with autografts and allografts: A histologic comparison. *J Perio* 1981;52:297.